

Gastric cancer indocyanine green lymph node navigation surgery: systematic review

Beatrice Molteni,¹ Paola Porsio,¹ Sarah Molfino,¹ Marie Sophie Alfano,¹ Sara Benedicenti,¹ Fausto Catena,² Luca Ansaloni,³ Nazario Portolani,¹ Gianluca Baiocchi¹

¹Department of Surgery, ASST Spedali Civili Brescia, Brescia; ²Department of Emergency Surgery, Maggiore Hospital, Parma; ³Department of General Surgery, Cesena Hospital, Cesena, Italy

Abstract

Sentinel lymph node (LN) biopsy is a common practice to determinate if a lymphadenectomy is needed in various malignancies. Recent studies have investigated the possibilities to extend sentinel LN biopsy in gastric cancer. Indocyanine green (ICG) is a diagnostic reagent recently introduced in sentinel LN biopsy field. This review aims to determinate the feasibility to use ICG to detect sentinel LN in gastric cancer.

Introduction

Indocyanine green (ICG) is a diagnostic reagent used since long time for assessment of hepatic function and cardiac output. It is also used as a dye tracer for gastric cancer as the blue dye. Unfortunately ICG was not well observed by naked eyes, than devices to better detect ICG were developed. ICG absorbs light in the near infrared range between 600 to 900 nm and emits fluorescence between 750 to 950 nm. Near infrared fluorescence imaging

system developed are the following: Photodynamic Eye (PDE, Hamamatsu Photonics, Hamamatsu, Japan) imaging camera system,¹ SPY system (Novadaq Technologies, Concord, ON, Canada) and the Fluobeam (Fluoptics, Grenoble, France). Several others imaging systems have been used in clinical studies but are not available in the market as: HyperEye (HEMS)² (Kochi Medical School, Kochi, Japan), the FLARE and Mini-FLARE³ (Beth Israel Deaconess Hospital, Boston, MA, USA), the FDPM imager⁴ (Texas Medical Center, Houston, TX, USA), and a prototype camera system from Munich⁵ (Technical University Munich, Munich, Germany and SurgOptix Inc., Redwood Shores, CA, USA).

Sentinel LN is defined as a node that directly receives lymphatic drainage from a primary tumor.⁶ Sentinel LN biopsy is a common practice to determinate if a lymphadenectomy is needed in various malignancies, for example breast and skin cancer. Recently gastric cancer sentinel node biopsy was investigated. Prospective studies have successfully demonstrated the feasibility of sentinel LN biopsy in gastric cancer.⁷⁻¹⁰ Except for JCOG0302 trial that shown high false negatives, that was probably because just one plan for intraoperative histological examination was not an appropriate method.¹¹ Various methods are described to map sentinel LN as: isosulfan blue and ICG were used as dye tracer. Successively radioactive tracer with Technetium-99 colloid was introduced, alone or associate with dye tracer. Dual tracer method for sentinel LN mapping is confirmed to be safe and effective.¹² Recently ICG fluorescence method was introduced, using near infrared light to detect sentinel LN.

Our goal is to determinate the feasibility of single tracer ICG sentinel LN mapping in gastric cancer patients.

Correspondence: Beatrice Molteni, Department of Surgery, ASST Spedali Civili Brescia, Piazzale Spedali Civili 1, 25123, Brescia, Italy. E-mail: beatrice.molteni@hotmail.com

Key words: Gastric cancer; indocyanine green; sentinel lymph node.

Contributions: MB and PP, study and manuscript conception, online search and article selection; BG, re-checking and solve doubt; MS, AMS, BS, CF, AL, PN, revising and contribute to final version.

Conflict of interest: the authors declare no potential conflict of interest.

Received for publication: 26 February 2018.

Revision received: 25 March 2018.

Accepted for publication: 19 April 2018.

©Copyright B. Molteni et al., 2018

Licensee PAGEPress, Italy

Journal of Peritoneum (and other serosal surfaces) 2018; 3:97

doi:10.4081/joper.2018.97

This article is distributed under the terms of the Creative Commons Attribution Noncommercial License (by-nc 4.0) which permits any non-commercial use, distribution, and reproduction in any medium, provided the original author(s) and source are credited.

Methods of research

Literature search strategy

We carried out electronic research during July 2017. PubMed, EMBASE and Cochrane Library database were examined. Key words for the research were gastric or stomach cancer, indocyanine green, and lymph node. Only English language articles were included. References from included studies were screened to search for additional potentially relevant articles.

Inclusion and exclusion criteria

We consider as inclusions criteria the following: original articles concerning LN navigation surgery in gastric cancer using ICG with near infrared light.

Exclusion criteria are as follow: reviews, case reports, meta-analyses, abstract, posters or letters; animal experimental trial; dye

ICG tracer detected by naked eye; studies that include dual tracer; studies without sufficient data.

Online search and article selection were performed by two investigators independently (M.B. and P.P.) a third investigator re-checked originals articles and discuss any doubt (B.G.).

Data extraction and quality assessment

Data were extracted by two authors (M.B. and P.P.) and excel table were filled including author and publication time, number of patients, clinical T stage, surgical method (laparoscopic or open), injection method, time of injection, dose of ICG injected, type of camera used and test results (identification rate, false negative and number of LN included into basin). Identification rate was defined as the number of patients who underwent a successful sentinel LN biopsy by the number of patients in whom a sentinel LN biopsy was attempted. False negative was defined as a negative sentinel LN with positive LN non-sentinel. False negative rate was the number of false negative by the number of LN metastases (Figure 1).

Results

A total of 390 records were identified: 132 PubMed, 238 EMBASE, 18 Cochrane and 2 from others sources. After duplicate removal a total of 266 records were screened and we found that of them 184 were irrelevant; the main part regard sentinel LN in gastric cancer without ICG usage, or ICG involved in others surgical techniques. Finally 82 articles remained for potentially inclusion, and full text was read. 64 full texts were excluded in the final screening. The mainly reasons for excluding studies were: non original articles (such as *review*), animal experiment, in vitro experiment, the use of dual tracer and the use the dye tracer with naked eye.

18 studies were included in the review. Publication time was from 2004 to 2017. The sample size varied from 3 to 212 patients. Clinical T stage varied from T1 to T4, with a higher prevalence of T1 and T2, all N0 and M0. Both laparoscopic and open surgery technique were included.

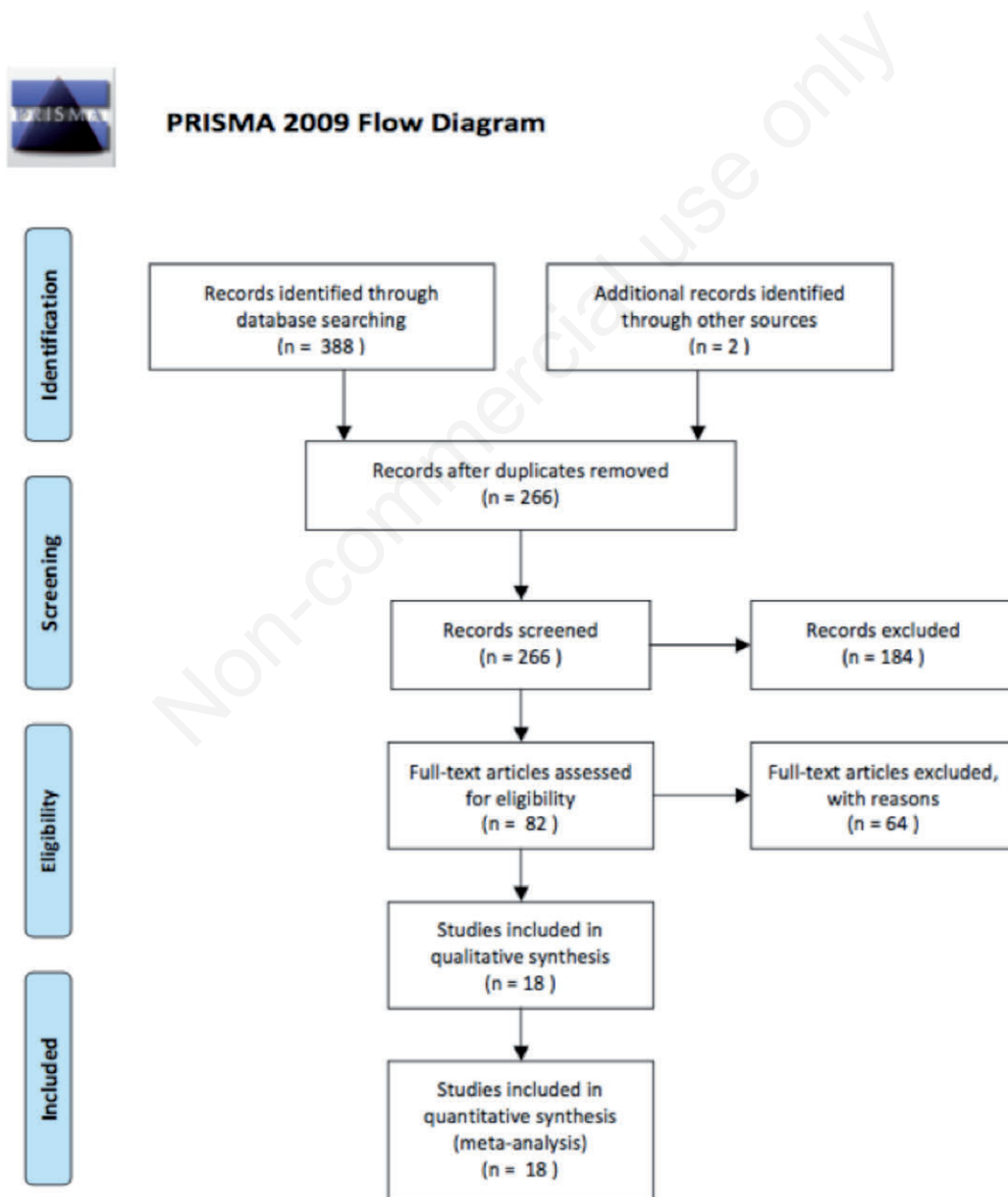


Figure 1. Prisma flow diagram.

No adverse event associated with sentinel LN biopsy or ICG injection was described. ICG was injected from 3 days before surgery to intraoperatively, injection way was submucosal or subserosal. Camera system used to detect sentinel LN were PDE, infrared ray electronic endoscopy (IREE), miniFLARE, Infrared ray laparoscopic system (IRLS), PINPOINT, HEMS. Amount of ICG varied from 0.2 mL to 1 mL x 4 point of injection, dilution 33 µg/mL to 1.25 mg/0.5 mL. Identification rate range was between 90.90% and 100% average of sentinel LN detected was 2.9-10.5. False negative rate varied from 0% to 60%.

Discussion

False negative

Higher false negative rate was found from Kusano *et al.* (60%) he showed that increasing pathological T stage from T1 to T3 a higher false negative rate was found (T1 33.3%, T2 66.7%, T3 75%)¹³ (Table 1). Also Ishikawa *et al.* found a high percentage of false negatives (50%). They found 2 metastatic LN, and 1 false negative in an obese patient, the LN was located in sentinel LN basin, it was not bright at laparoscopic founding, but a positive staining was observed postoperatively.¹⁴ The same appended to Kinami, 1 patient had LN micrometastases diagnosed in a LN non-bright intraoperatively, but postoperative was found to be staining. Other bright LN in the same basin was found to be metastatic cutting other slices of the paraffin blocks.¹⁵ Although high false negative rate was found by some author, the false negative LN was located in the same LN basin. The mislead false negative can be overcome examining all LN founded in LN basin.

Tajima *et al.* had 35% false negative rate. The pT1 of cT1 percentage was 81%, and pT2 and pT3 was respectively 16.2% and 2.7%. For cT2 and cT3 the percentage of pT1 was 5.3%, and for

pT2 and pT3 was respectively 52.6% and 42.1%. False negative rate for cT1 was 14.3, and for cT2 and cT3 50%.¹⁶

Tajima *et al.* had a false negative rate lower in laparoscopic sentinel LN navigation surgery (24%). False negative rate was found to be higher in T2 group vs T1 (28.6% vs 20%). It was shown that the risk of metastasis in LN outside lymphatic basin in patients without metastases in sentinel LN was 0%, and was 23% in patients with sentinel LN metastases (12.5% in T1 and 40% in T2).¹⁷ The concept of sentinel LN as lymphatic basin dissection can probably predict the absence of metastases outside of lymphatic basin. A selective lymphadenectomy can be performed avoiding the extended lymphadenectomy.

Tummers *et al.* analyzed cTx patients, their false negative rate was 24%. Accuracy rates decrease with the T state, for pTx, pT1, pT2, pT3 and pT4 were 100%, 100%, 100%, 90% and 0%. False negative were found in T3 and T4 tumours, with a large tumor diameter. In 8/22 patients sentinel LN were detected outside of standard resection plan. In this study 1 of the false negative LN was found in the same basin of one sentinel LN.¹⁸ The experience of Tummers,¹⁸ Tajima,^{16,17} Kusano,¹³ showed as increasing T stage increase the risk of false negative. Probably this technique should be applied only in T1 stage. Unfortunately western experience is poor of early stage gastric cancer. Tummers¹⁸ report the mayor western experience in sentinel LN navigation surgery, and demonstrated that in T2, T3 and T4 stage a standard lymphadenectomy should probably be the best choice. Asian experience is more positive regarding this new technique. The mayor part of gastric cancer is an early stage that lead to promote this technique to avoid unnecessary lymphadenectomy and probably less invasive resection.

ICG injection

In a prospective multicenter trial Takahashi demonstrate the superiority of infrared light observation instead of naked eye observation concerning identification rate (100% vs 80%),^{19,20} confirmed

Table 1. False negative.

Author	Year	cT-stage	pT-stage	N° patients	N° metastatic sentinel LN	False negative	False negative rate (%)
Takahashi N	2017	T1		44	7	0	0
Kinami S	2016	T1	T1a 29/T1b 31/T2 10/T3 2	72	11	1	9
Takahashi N	2016	T1/T2		36	5	0	0
Tummers Q	2016	Tx	Tx2/T1 5/T2 4/T3 10/T4 1	22	8	2	25
Yano K	2011	T1/T2		130	31	0	0
Miyashiro I	2011	T1	4 T1a/5 T1b/1 T2	10	3	1	33
Nimura H	2004	T1/T2		84	11	0	0
Ishikawa K	2007	T1	pT1 (14)/pT2 (2)	16	2	1	50
Yoshida M	2012	T1/T2		13	1	0	0
Kelder W	2010	T1	183 T1/ 25 T2/ 4 T3	212	34	1	3
Kusano M	2008	Tx	T1/T2/T3	22	10	6	60
Tajima Y	2010	T1 T2	52T1/ 21T2/ 4T3	77	17	4	24
Ohdaira H	2007	Tx	T1	52	2	0	0
Miyashiro I	2008	T1		3	0	0	
Ohdaira H	2009	T1 T2	23T1 / 7 T2	30	4	0	0
Ohdaira H	2009	T1 T2		14	3	0	0
Ohdaira H	2017	T1/T2		6	1	0	0
Tajima Y	2009	37 T1/ 19 T2 T3	23 T1/ 16 T2/ 8 T3	56	17	6	35

by other study in which identification rate was similar (100% vs 78%)²¹ (Table 2). Identification rate was 98,8% in Nimura *et al.* study. In one patient was not possible to identify sentinel LN probably because was extremely obese. ICG alone was able to detect sentinel LN that includes metastasis in 7 patients instead of 11 LN identified with IREE.²² Kelder as well has one obese patient in which was not possible detect sentinel LN with IREE. The identification rate was much superior with IREE than naked eye.¹⁹ ICG originally was used as a dye tracer ad methylene blue. Since near infrared light was introduced in the clinical practice, identification rate of sentinel LN was increased. This new technique seems to be safe and effective in sentinel LN navigation surgery.

Kinami *et al* proposed as optimal tracer setting to use with the PDE an endoscopic submucosal injection of 0.5 ml of 50 µg/mL ICG at four points surrounding the tumor the day prior to surgery. Some preliminary cases were examined with an ICG concentration of 2.5 mg/mL, 125 µg/mL, 125 µg/mL, 50 µg/mL, and 5 µg/mL for 0,5 mL x 4 injection point. They decide to evaluate 0.2 mL x 4 and 0.5 mL x 4 points, the median number of bright LN was not significantly different between two groups: 6 (range 3-11) for 0.5 mL and 6 (2-7) for 0.2.¹⁵

Yoshida *et al.* have developed a new device for near infrared light, it can be used under room light. He tried the first 2 preliminary cases one with 100 µg/mL ICG 1 day before surgery, and the second one 25 µg/mL the day before too. The first case was too intense and too many fluorescence-positive LN were detected. In the second patient the fluorescence was too faint. Than 50 µg/mL ICG injection intraoperatively was tried, but was too intense and have too many ICG positive LN. Finally they define the best ICG concentration as 50 µg/mL, injected the day before surgery, with a number of LN detected 3.6.²³ Evaluating the dose and the timing the ideal dose seems to be 50 µg/mL ICG injected the day before surgery.

Takahashi *et al.* attempted to quantitatively assess the visual

evaluation of ICG image. They grouped on a black table LN dissected in ICG positive lymphatic basin into two group: ICG positive and ICG negative. Then LN were photographed under infrared light observation in a black box and software analyzed the intensities. They demonstrated the intensity was significantly different between ICG-positive and ICG negative LN (0.323±1.56 vs 0.639±1.93).²¹

ICG injection timing is debated. Intraoperative injection is less invasive for patients instead an endoscopy performed the day prior to surgery. Tajima *et al.* in their study resulted that the mean number of SNs was significantly higher in the preoperative ICG injection group than in the intraoperative ICG injection group (9.9±7.5 vs 4.1±5.0, P<0.0003). Preoperative ICG injection was superior in terms of the accuracy and false negative rates (100% vs 73.9%, P=0.0039 and 0% vs 60.0%, P=0.0345, respectively). Even is more invasive, preoperative ICG injection seems to be superior than intraoperative.¹⁶

ICG lymphography might could helps in identify potentially pathological LN outside of standard resection plan, and could guide extended lymphadenectomy even in patients pretreated with chemotherapy.¹⁸ Unfortunately the literature is poor of articles that include advanced gastric cancer LN navigation surgery. More studies are needed to prove the effectiveness of ICG in advanced gastric cancer. Some authors demonstrate that increasing T stage, false negative rate is higher.¹⁸ Probably pathological LN lose their function, the in and the outflow, and that make impossible to inflow ICG.¹⁸

Sentinel LN basin is a lymphatic area including SLNs and downstream lymphatic flow. Tummers confirms that sentinel LN basin dissection is better than LN picking method.¹⁸ Kelder confirm the higher intraoperative detection rate with frozen section of LN metastases: 92.3% for basin dissection vs 50% for the picking method.¹⁹

Ohdaira H support the LN basin dissection, additional dissection

Table 2. ICG Injection.

Author	Year	ICG injection	Amount of ICG	Submucosal/subserosal	Time from injection to biopsy	Average of LN per patient	SLN identification rate (%)
Takahashi N	2017	I	0.5 mL	SM	20 min	7.9±5.6	100
Kinami S	2016	D	0.5 mL x4: 0.2x4	SM	24 h	6	
Takahashi N	2016	I	0.5 mL x4 (5 mg/mL)	SM		9.2±5.9	100
Tummers Q	2016	I	0.4 mL x4 ICG and Nanocolloid (1.6 mL ICG solution=0.05 mg ICG + 0.1 mg nanocolloid)	SS	0 min	3.1	95.45
Yano K	2011	I	0.5 mL x4 (0.5 mg/mL)	SM	20 min		100
Miyashiro I	2011	I	2-4 mL (0.25-1.25 mg/0.5 mL)		5 min	3,1±1,5	100
Nimura H	2004	I	0.5 mL x4 (5 mg/mL)	SM	20 min	10.5±6.6	98.80
Ishikawa K	2007	I	0.5 mL x4 (5 mg/mL)	SM	20 min	2.9	100
Yoshida M	2012	D		SM	24 h	3.6±2.1	100
Kelder W	2010	I	0.5 mL (5 mg/mL)	SM	20 min	6	99.52
Kusano M	2008	I	0.5 mL x4 (0.5%)	SS		3.6±4.5	90.90
Tajima Y	2010	I, 3D	0.5 mL x4 (0.5%)	SM/SS	1-3 day/intraop	7.5	94.80
Ohdaira H	2007	I	0.5 mL x4 (5 mg/mL)	SM	20 min		100
Miyashiro I	2008	I, D	2-4 mL	SM	Immediately/24 h	3	100
Ohdaira H	2009	I	0.5 mL x4 (5 mg/mL)	SM	20 min	4.8	100
Ohdaira H	2009	I	0.5 mL x4 (5 mg/mL)	SM	20 min		100
Ohdaira H	2017	D	50 g/mL for 5 case; 33 g/mL for 1 case	SM		7±4.7	100
Tajima Y	2009	I, 3D	0.5 mL x4 (0.5%)	SM/SS		7.2±7	94.40

of ICG - positive lymphatic basin detected by LN navigation surgery should be performed to confirm the absence of LN metastases.²⁴

Concerning the pathological examination, the use of immunohistochemistry with anti-cytokeratin antibody is demonstrated to be superior to hematoxylin and eosine (H&E) in diagnosing of LN metastasis. 13% of patients diagnosed with no metastasis by H&E staining were judged LN positive by IHC staining.²⁵ Detection of micrometastases is an important factor to follow up because of the increased risk of recurrence.²⁶ Anyway all LN with micrometastases was ICG positive, and included in SN basin dissection.²⁵ One sentinel LN with micro metastases was missed at intraoperative evaluation, but detected with IHC.²⁷

Camera system

Nimura *et al.* started the evaluation of sentinel LN using ICG fluorescence-guided method with IREE.²⁷ Kinami *et al.* started to use PDE for ICG fluorescence detection¹⁵ (Table 3).

IREE was used in 8 studies and 6/8 studies had 100% detection rate, and the lowest rate was 98.8%. PDE was used in 6 studies, and had a range of identification rate from 90,9% to 94.8% using PDE alone, but associated with colour or IREE raised 100%. IRLS was firstly described from Takahashi *et al.* for laparoscopic detection of sentinel LN, the identification rate with this device was 100%. New cameras were described from others author, Mini Flare with identification rate 95.45%, HEMS and PINPOINT identification rate were 100% both. False negative rate range for PDE was from 9% to 60%, except for Miyashiro that did not found any metastatic LN. The range for IREE was from 0% to 50%, in 6/8 studies the percentage was 0%. Different types of camera were used in different studies. More studies are needed to compare the camera type.

Detection rate and the mean number of sentinel LN were similar for laparoscopic and open surgery (94.7% vs 94.9%, 7.9 vs

7.2). False negative rate was 25% for laparoscopic surgery and 23.1% for open surgery. Ohdaira *et al.* support the use of ICG for sentinel LN detection even in patients who had received previously an endoscopic resection.²⁷⁻²⁹ There is no difference in laparoscopic and open surgery.

Conclusions

ICG fluorescence navigation surgery seems to be safe in detection of sentinel LN in gastric cancer. High false negative rate was found in some studies, probably because the small number of the sample and in some cases in obese patients. Increasing T stage increase the risk of false negative. May IHC can helps to better detect micrometastases and to reduce false negative. More studies are needed to overcome this problem. New cameras may can help to better detect sentinel LN. ICG navigation surgery seems to be safe in both, open and laparoscopic approaches.

More studies are needed to better understand the role of ICG in gastric cancer navigation surgery.

References

1. Tagaya N. Intraoperative identification of sentinel lymph nodes by near-infrared fluorescence imaging in patients with breast cancer. *Am J Surg* 2008;195:850-3.
2. Handa T. New device for intraoperative graft assessment: HyperEye charge-coupled device camera system. *Gen Thorac Cardiovasc Surg* 2010;58:68-77.
3. Troyan S. The FLARE intraoperative near-infrared fluores-

Table 3. Camera System.

Author	Year	Camera	Surgery	Sentine LN identification rate (%)	False negative rate (%)
Takahashi N	2017	IRLS (infrared ray laparoscopic system)	Laparoscopy	100	0
Kinami S	2016	PDE	32 open/40 laparoscopy		9
Takahashi N	2016	IRLS (infrared ray laparoscopic system)	17 open/19 laparoscopy	100	0
Tummers Q	2016	Mini Flare NIR		95.45	25
Yano K	2011	IREE	Open/laparoscopy	100	0
Miyashiro I	2011	PDE + color	Laparoscopy	100	33
Nimura H	2004	IREE	65 open/19 laparoscopy	98.80	0
Ishikawa K	2007	IREE	Laparoscopy	100	50
Yoshida M	2012	HEMS (HyperEye Medical System)	Laparoscopy	100	0
Kelder W	2010	IREE	120 open/92 laparoscopy	99.52	3
Kusano M	2008	PDE	18 open/4 laparoscopy	90.90	60
Tajima Y	2010	PDE	Open 39/38 laparoscopy	94.80	24
Ohdaira H	2007	IREE	Open/laparoscopy	100	0
Miyashiro I	2008	PDE + IREE	Open	100	
Ohdaira H	2009	IREE	27 open/3 laparoscopy	100	0
Ohdaira H	2009	IREE	7 open/7 laparoscopy	100	0
Ohdaira H	2017	PINPOINT	Laparoscopy	100	0
Tajima Y	2009	PDE	Laparoscopy	94.40	35

- cence imaging system: a first-in-human clinical trial in breast cancer sentinel lymph node mapping. *Ann Surg Oncol* 2009;16:2943-52.
4. Marshall M. Near-infrared fluorescence imaging in humans with indocyanine green: a review and update. *Open Surg Oncol J* 2010;2:12-25.
 5. Crane L. Intraoperative multispectral fluorescence imaging for the detection of the sentinel lymph node in cervical cancer: a novel concept. *Mol Imaging Biol* 2010.
 6. Morton D. Technical details of intraoperative lymphatic mapping for early stage melanoma. *Arch Surg* 1992;127:329-99.
 7. Hiratsuka M. Application of sentinel node biopsy to gastric cancer surgery. *Surgery* 2001;129:335-40.
 8. Carlini M. Sentinel node in gastric cancer surgery. *J Exp Clin Cancer Res* 2002;21:469-73.
 9. Ichikura T. Sentinel node concept in gastric carcinoma. *World J Surg* 2002;26:318-22.
 10. Kitagawa Y. Radio-guided sentinel node detection for gastric cancer. *Br J Surg* 2002;89:604-8.
 11. Miyashiro I. High false-negative proportion of intraoperative histological examination as a serious problem for clinical application of sentinel node biopsy for early gastric cancer: final results of the Japan Clinical Oncology Group multicenter trial JCOG0302. *Gastric Cancer* 2014;17:316-23.
 12. Kitagawa Y. Sentinel node mapping for gastric cancer: a prospective multicenter trial in Japan. *J Clin Oncol* 2013;31:3704-10.
 13. Kusano M. Sentinel node mapping guided by indocyanine green fluorescence imaging: a new method for sentinel node navigation surgery in gastrointestinal cancer. *Dig Surg* 2008;25:103-8.
 14. Ishikawa K. Laparoscopic sentinel node navigation achieved by infrared ray electronic endoscopy system in patients with gastric cancer. *Surg Endosc* 2007;21:1131-4.
 15. Kinami S. Optimal settings and accuracy of indocyanine green fluorescence imaging for sentinel node biopsy in early gastric cancer. *Oncol Lett* 2016;11:4055-62.
 16. Tajima Y. Sentinel node mapping guided by indocyanine green fluorescence imaging in gastric cancer. *Ann Surg* 2009;249:58-62.
 17. Tajima Y. Sentinel node mapping guided by indocyanine green fluorescence imaging during laparoscopic surgery in gastric cancer. *Ann Surg Oncol* 2010;17:1787-93.
 18. Tummers Q. Near-infrared fluorescence sentinel lymph node detection in gastric cancer: A pilot study. *W J Gastroenterol* 2016;22:3644-51.
 19. Kelder W. Sentinel node mapping with indocyanine green (ICG) and infrared ray detection in early gastric cancer: an accurate method that enables a limited lymphadenectomy. *J Cancer Surg* 2010;36:552-8.
 20. Takahashi N. Laparoscopic sentinel node navigation surgery for early gastric cancer: a prospective multicenter trial. *Langenbecks Arch Surg* 2017;404:27-32.
 21. Takahashi N. Quantitative assessment of visual estimation of the infrared indocyanine green imaging of lymph nodes retrieved at sentinel node navigation surgery for gastric cancer. *BMC Surg* 2016 [Epub ahead of print].
 22. Nimura H. Infrared ray electronic endoscopy combined with indocyanine green injection for detection of sentinel nodes of patients with gastric cancer. *Br J Surg* 2004;91:575-9.
 23. Yoshida M. Indocyanine green injection for detecting sentinel nodes using color fluorescence camera in the laparoscopy-assisted gastrectomy. *J Gastroenterol Hepatol* 2012;12:29-33.
 24. Ohdaira H. Validity of modified gastrectomy combined with sentinel node navigation surgery for early gastric cancer. *Gastric Cancer* 2007;10:117-22.
 25. Yano K. The efficiency of micrometastasis by sentinel node navigation surgery using indocyanine green and infrared ray laparoscopy system for gastric cancer. *Gastric Cancer* 2012;15:287-91.
 26. Saito H. Recurrence in early gastric cancer: presence of micrometastasis in lymph node of node negative early gastric cancer patients with recurrence. *Hepatogastroenterol* 2007; 54:620-4.
 27. Ohdaira H. Tailoring treatment for early gastric cancer after endoscopic resection using sentinel node navigation with infrared ray electronic endoscopy combined with indocyanine green injection. *Digest Surg* 2009;26:276-81.
 28. Miyashiro I. Detection of sentinel node in gastric cancer surgery by indocyanine green fluorescence imaging: comparison with infrared imaging. *Ann Surg Oncol* 2008;15:1640-3.
 29. Ohdaira H. The possibility of performing a limited resection and lymphadenectomy for proximal gastric carcinoma based on sentinel lymph node navigation. *Surg Today* 2009; 39:1026-31.