

Appendix

Extra-peritoneal hysterоannessiectomy with eventual concomitant *en bloc* rectal resection and cytoreductive surgery in epithelial ovarian cancer (and other peritoneal surface malignancies): technical details

Luigi Frigerio, Marco Carnelli, Luisa Busci, Chiara Malandrino, Apollonia Verrengia, Chiara Bosisio, Giulia Montori, Federico Coccolini, Elia Poiasina, Luca Ansaloni

Figures

Figure 1

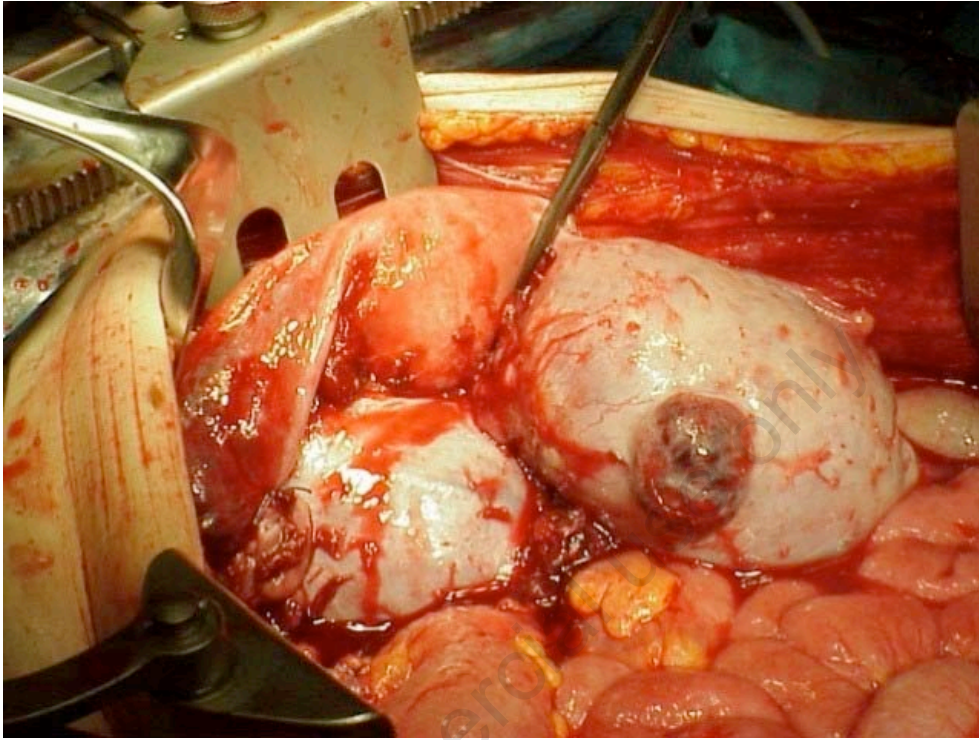


Figure 2

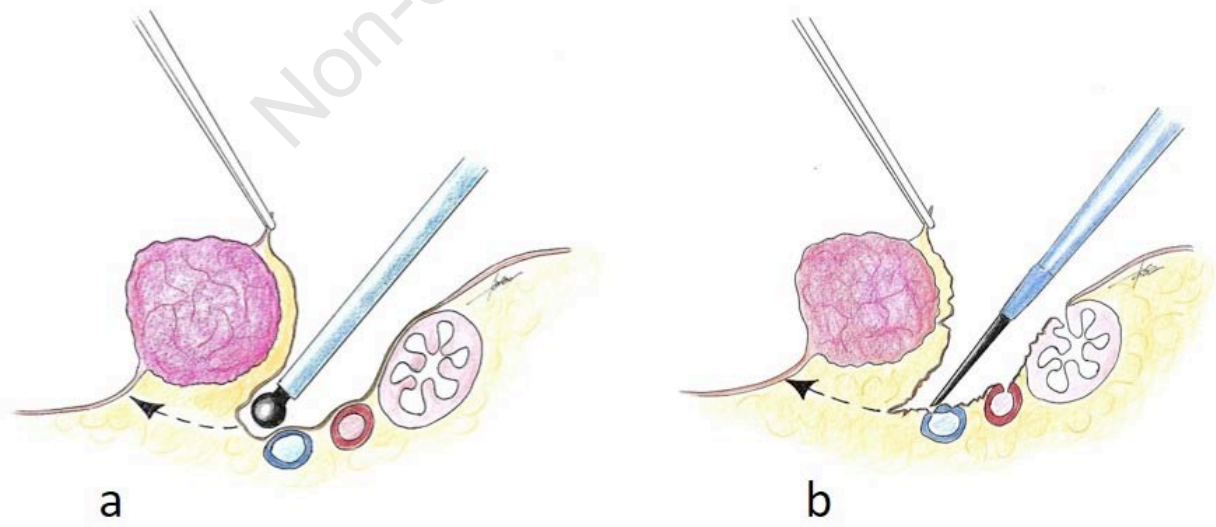


Figure 3

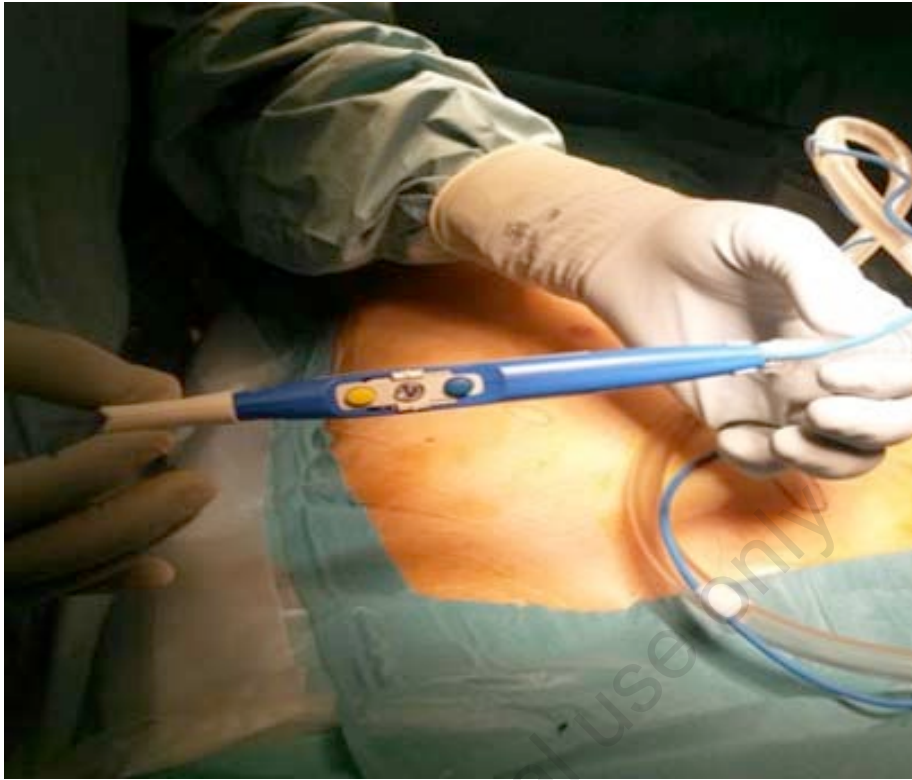


Figure 4

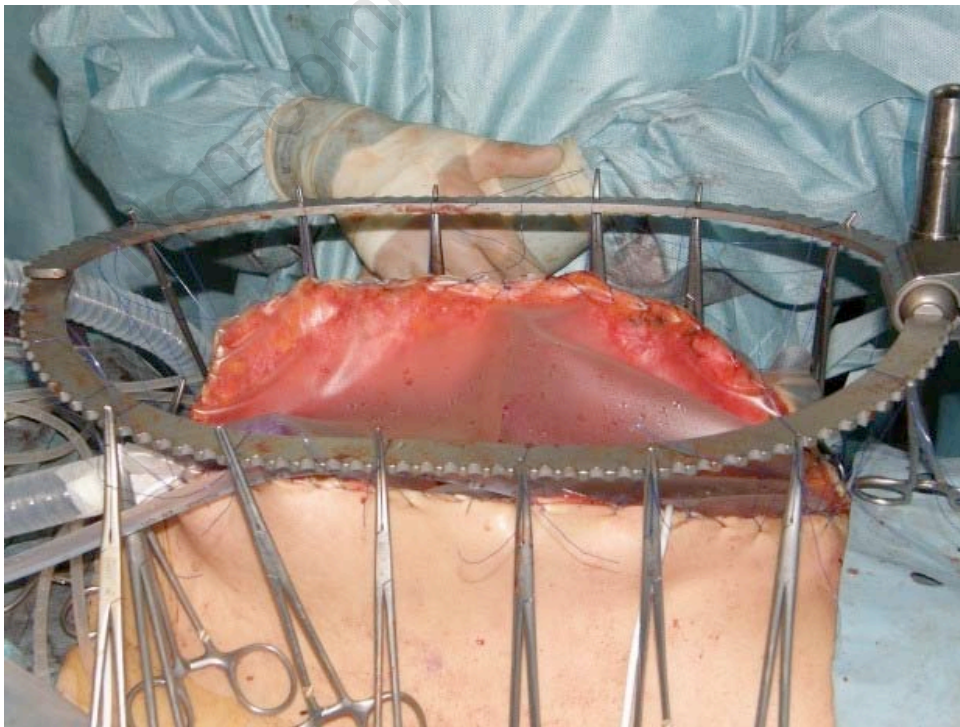
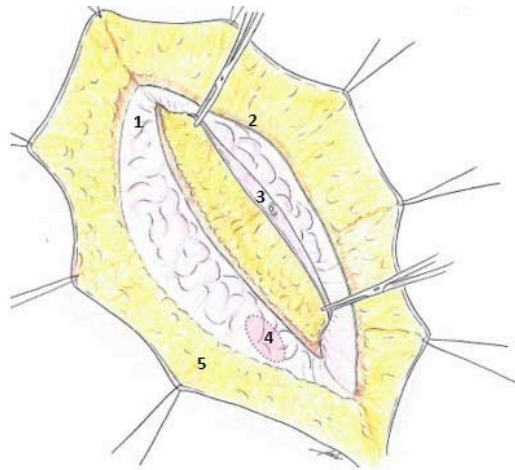
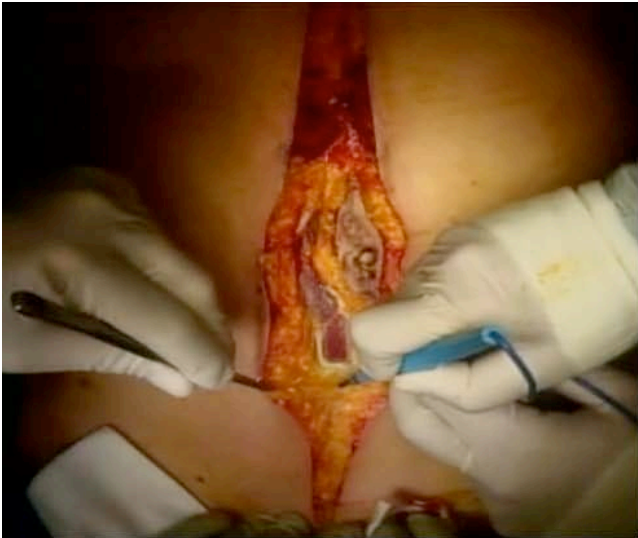


Figure 5



1-Anterior parietal peritoneum; 2-Posterior rectus sheath and its fascia; 3-Umbilicus; 4- Peritoneal window; 5-Subcutaneous fat.

Figure 6

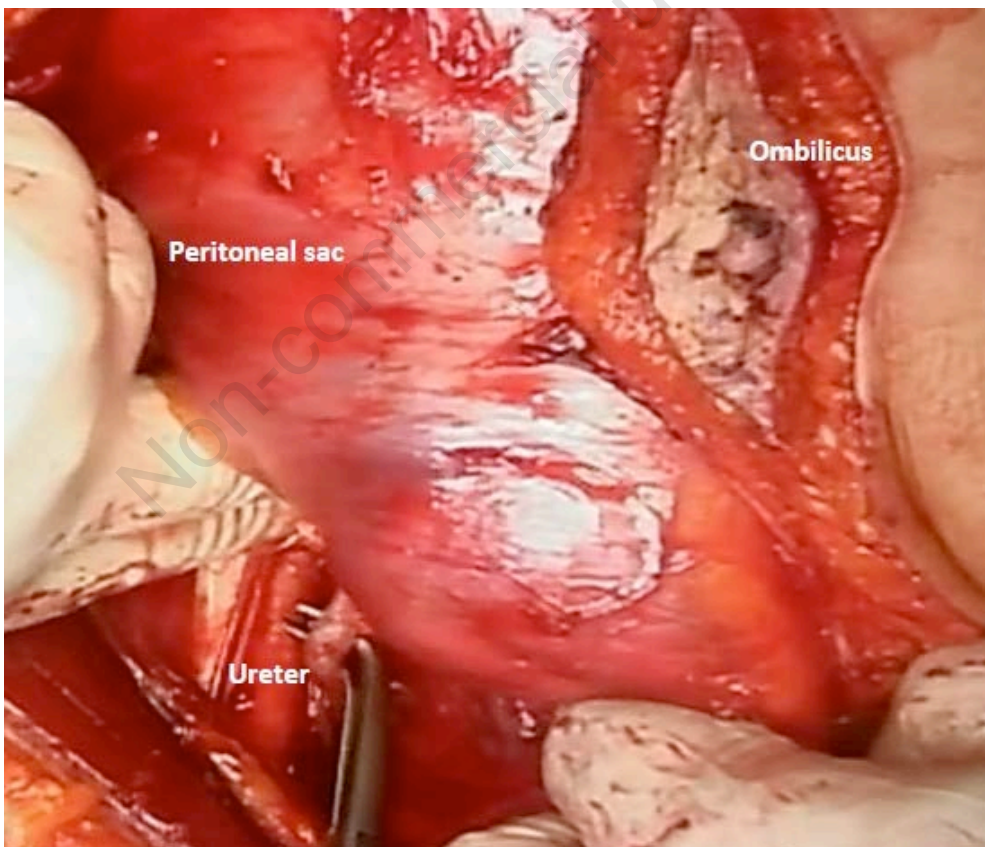


Figure 7

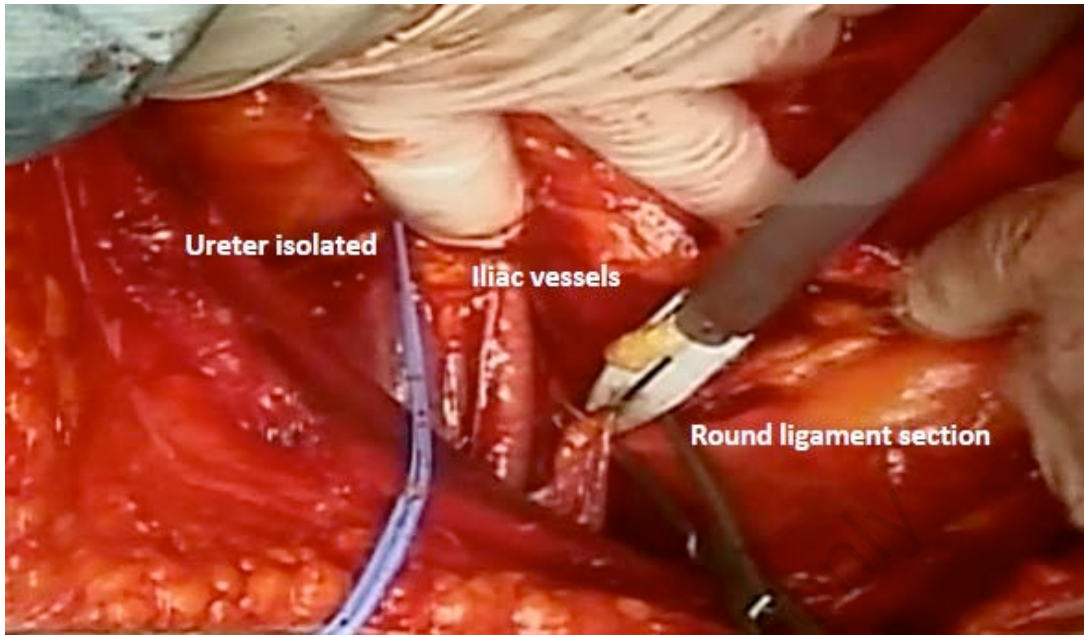


Figure 8

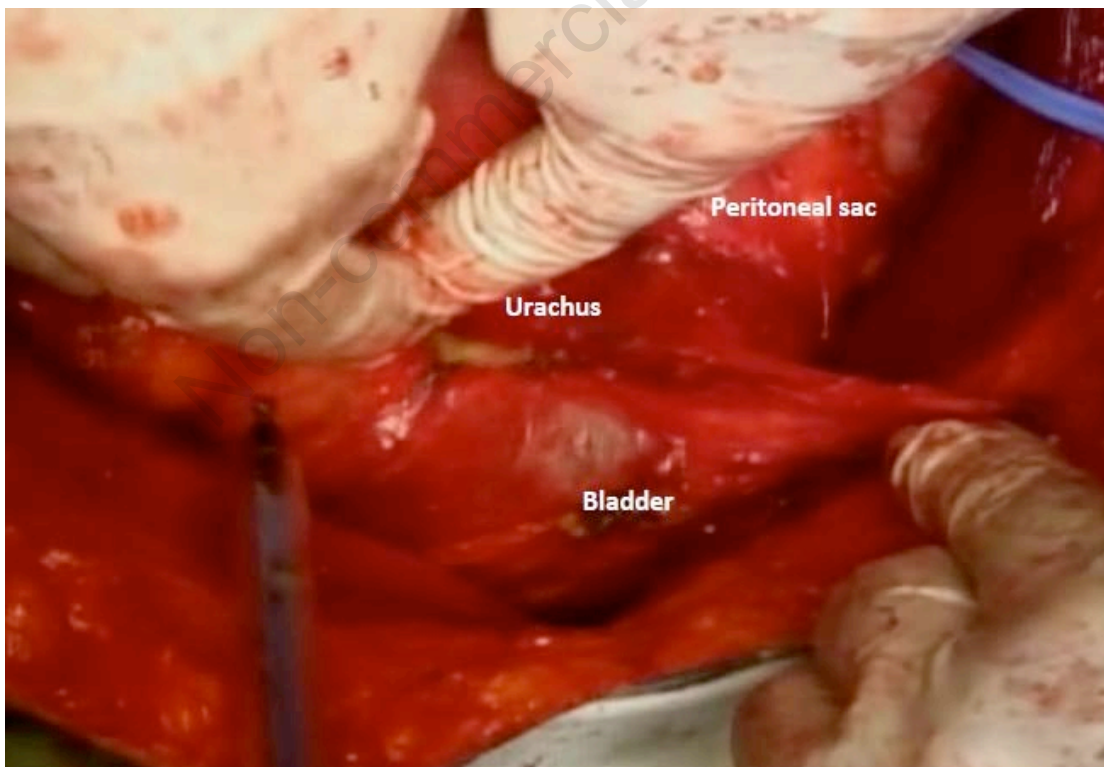


Figure 9

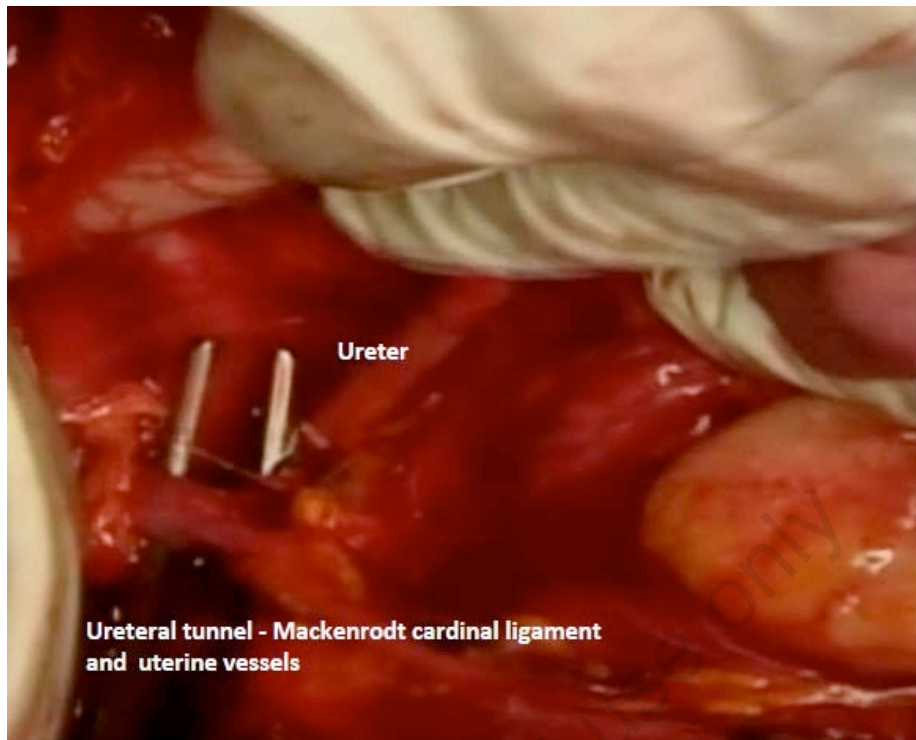


Figure 10

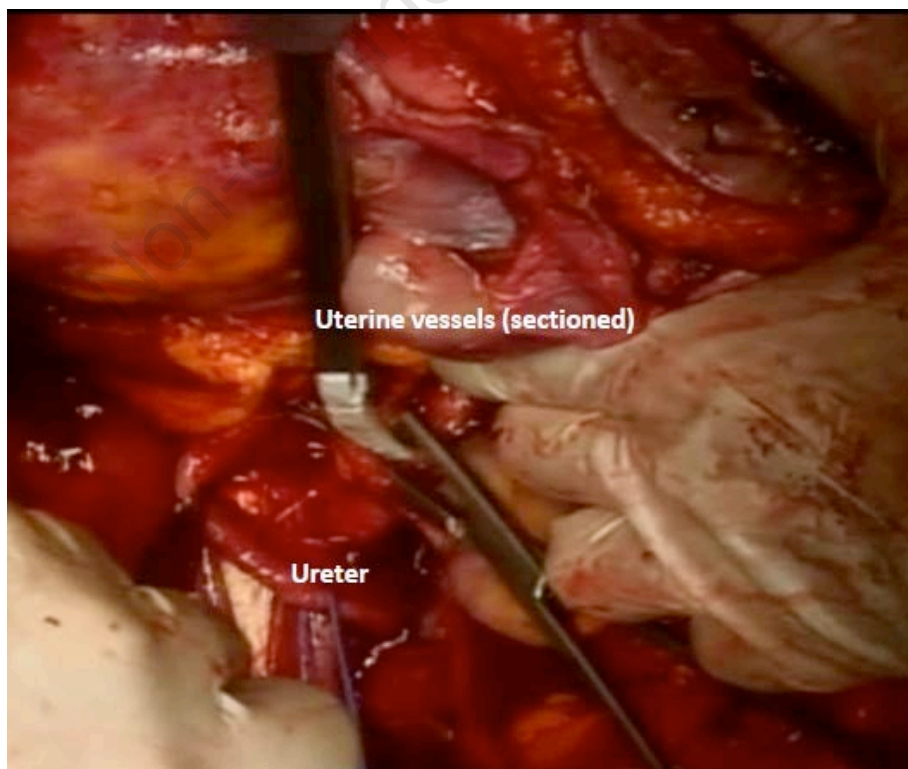


Figure 11

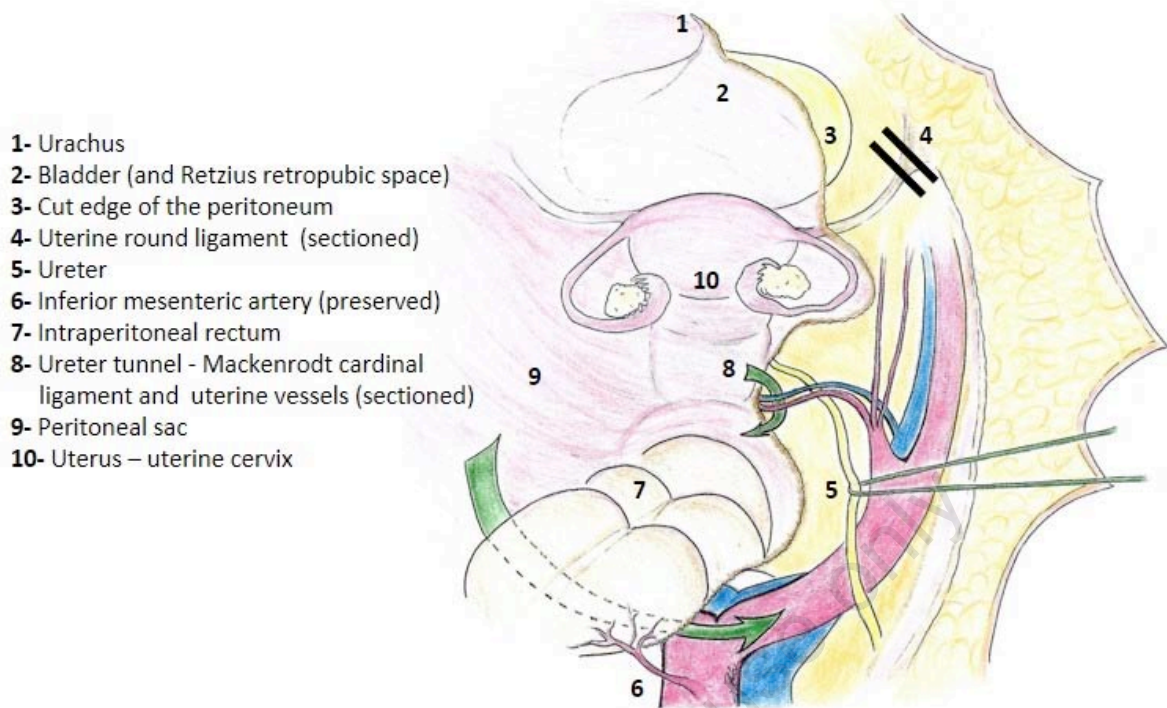
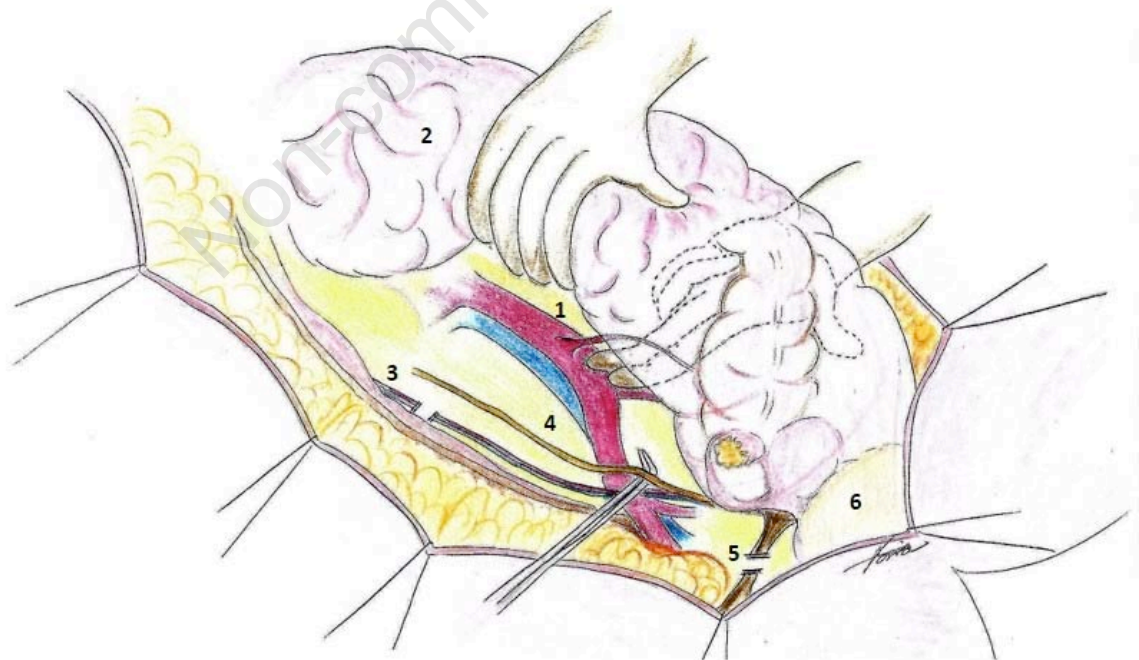


Figure 12



1- Inferior mesenteric artery (preserved); 2- Peritoneal sac; 3- Ovarian vessels (divided);
4- Ureter; 5- Uterine round ligament (divided); 6- Bladder

Figure 13

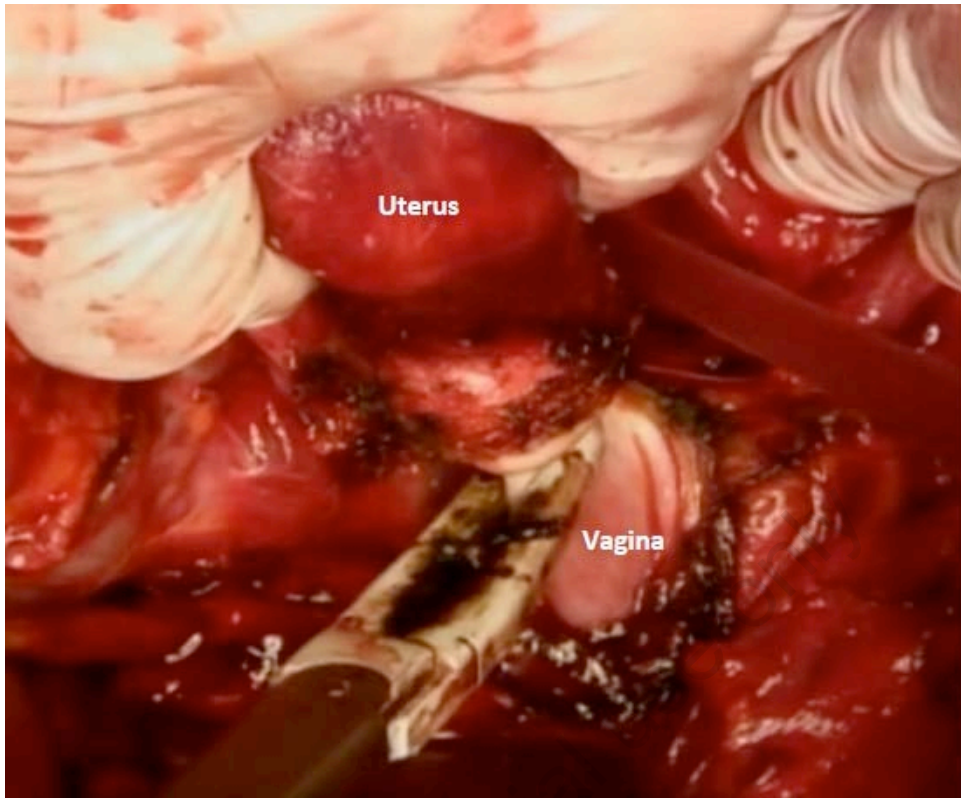


Figure 14

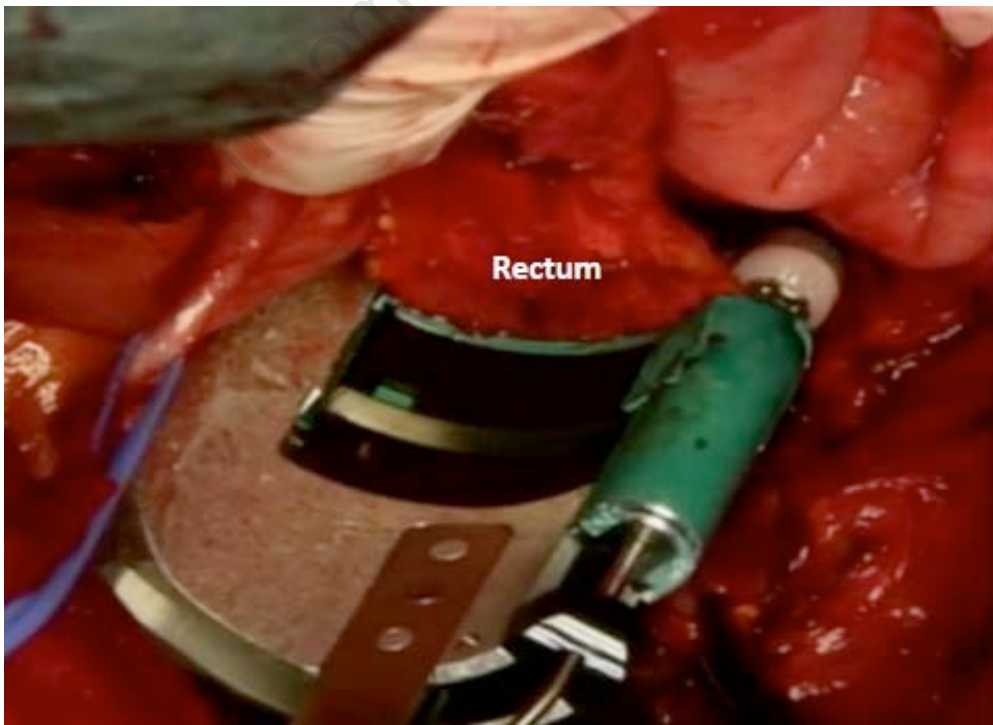


Figure 15

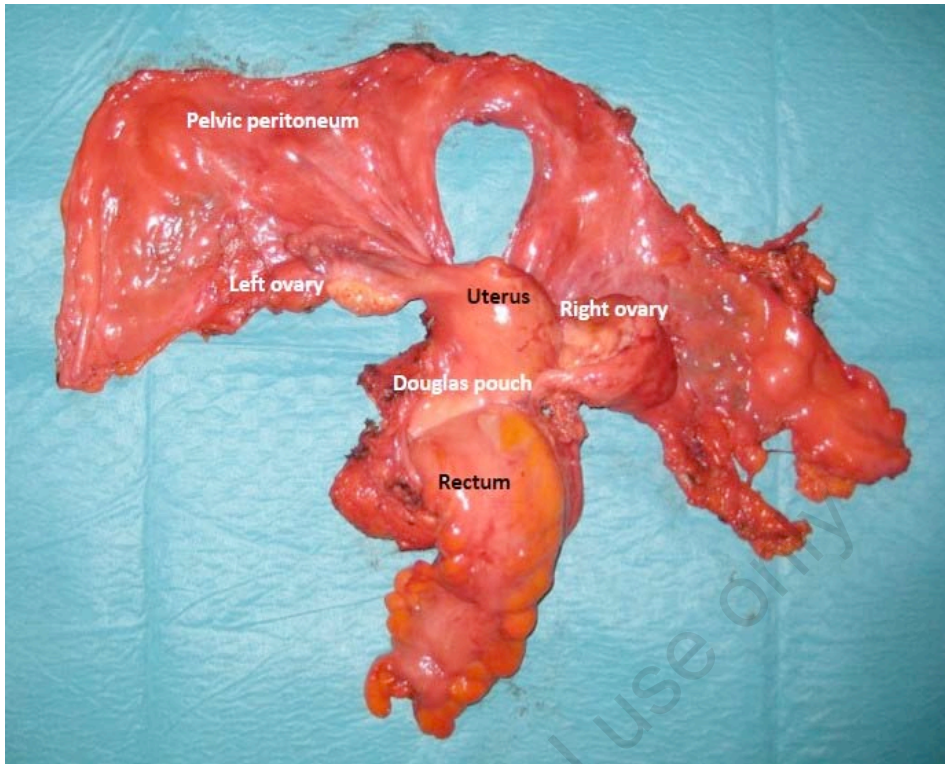
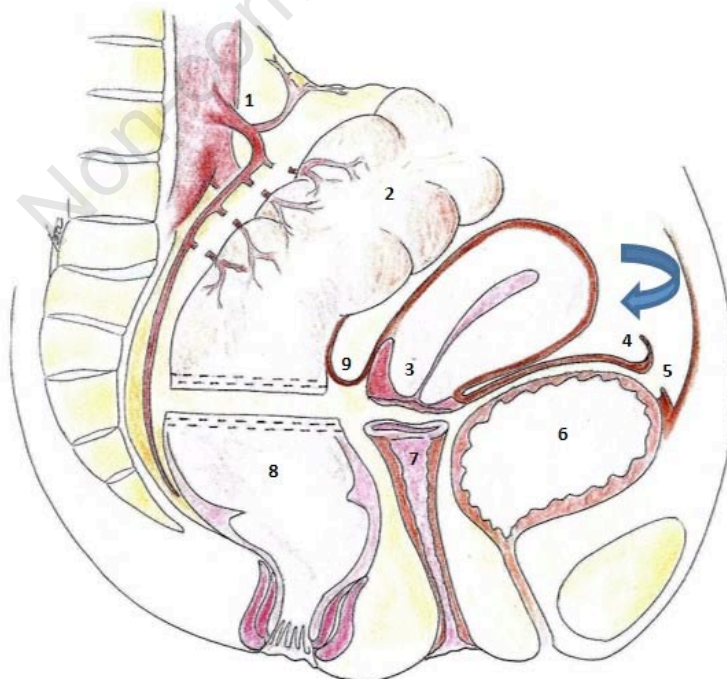


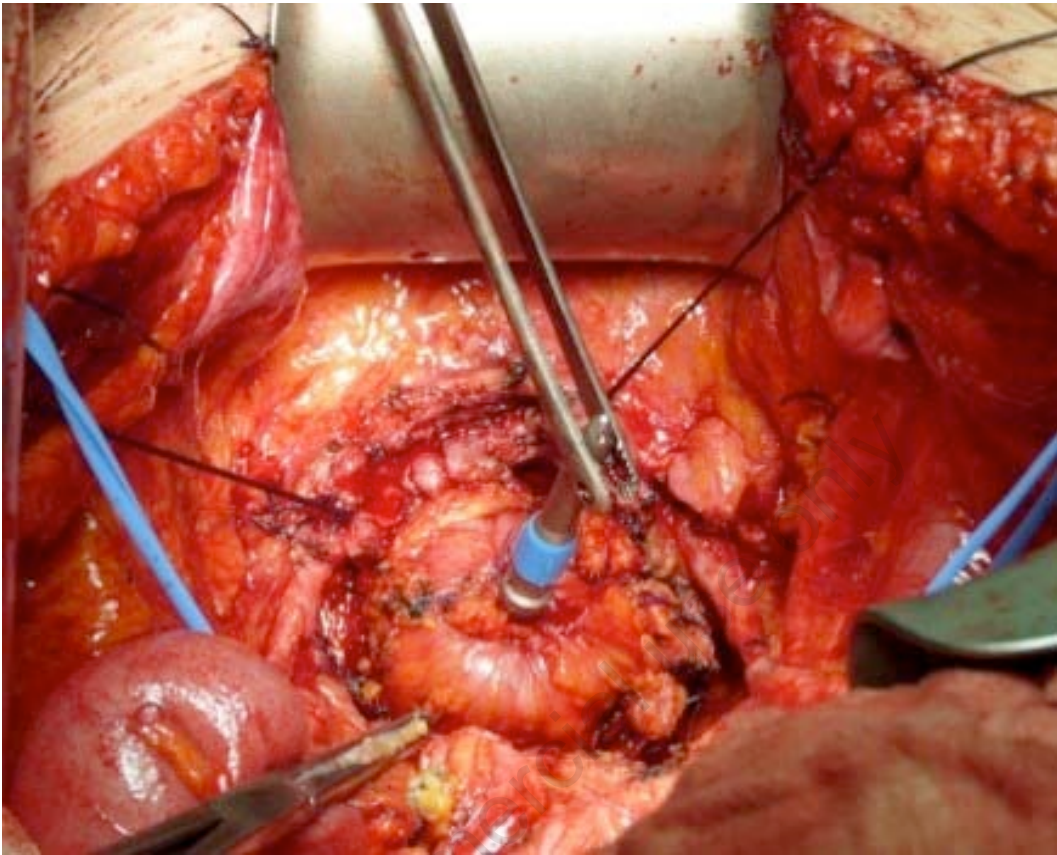
Figure 16



- 1- Inferior mesenteric artery (preserved); 2- Sigmoid; 3- Uterus – uterine cervix; 4- Urachus;
5- Cut edge of the peritoneum; 6- Bladder (and Retzius retropubic space); 7- Vagina;
8- Medium-low rectum (sectioned); 9- Douglas pouch

Figure 17

A



B

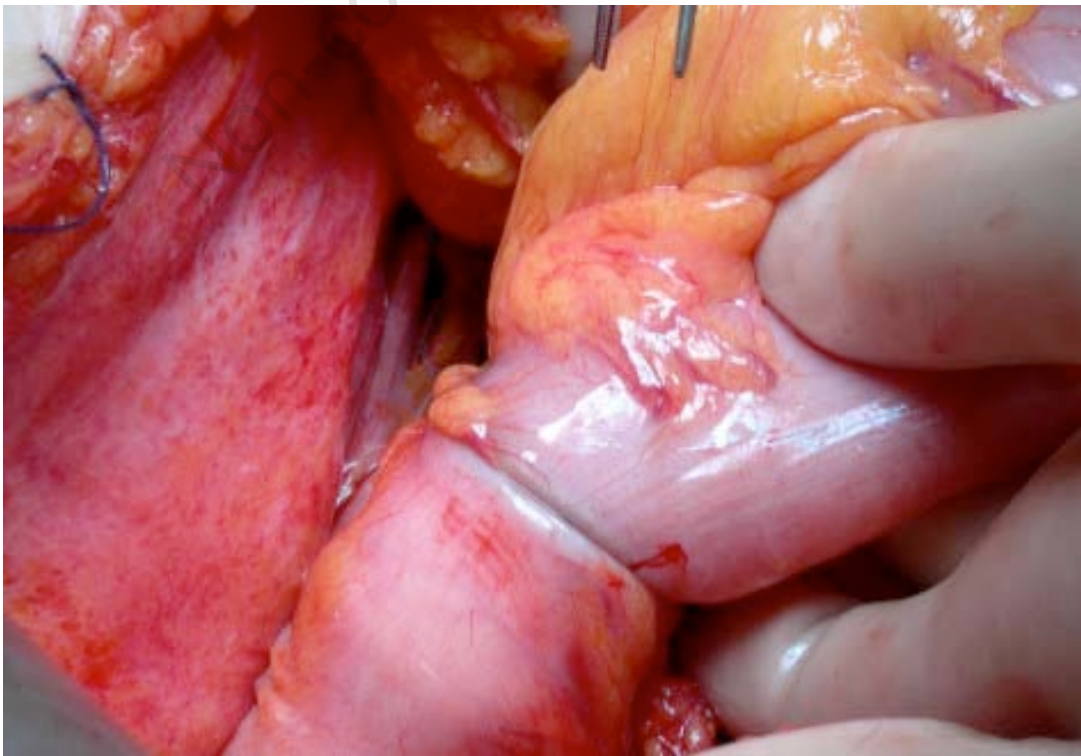
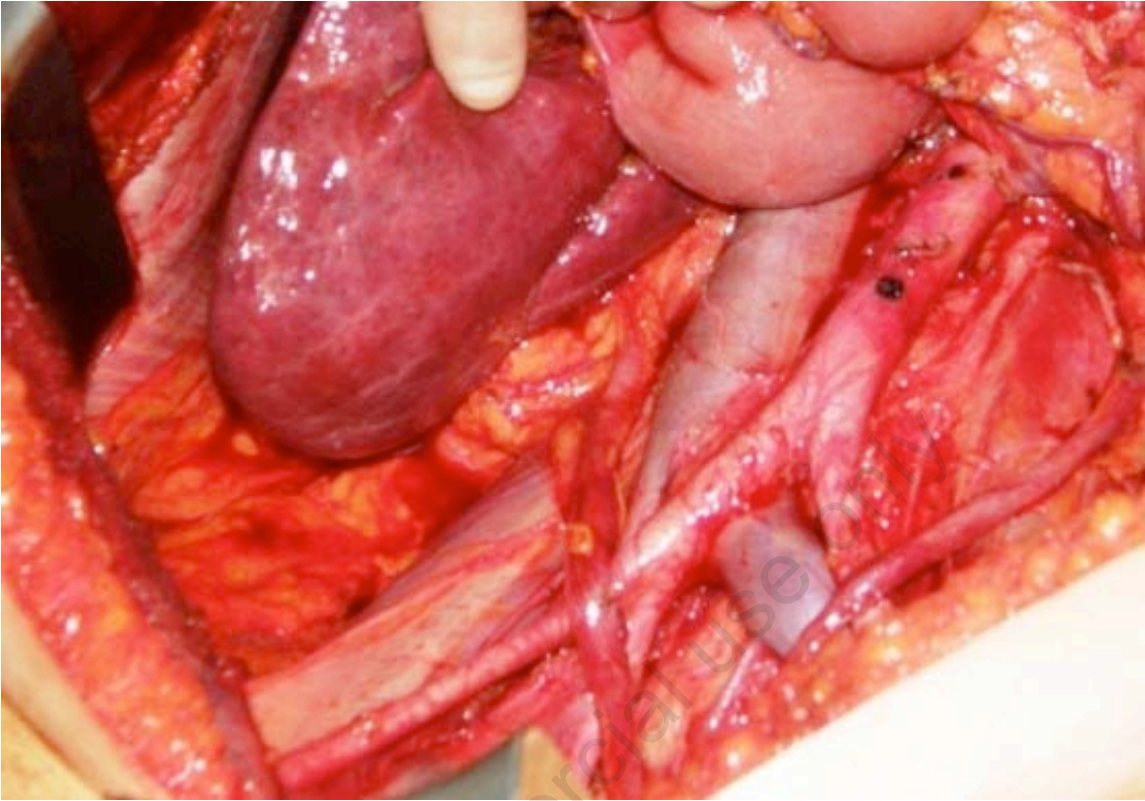


Figure 18



Non-commercial use only