

# Laparostomy in a rural hospital: an African case report for a very important tool to be spread and increased

Gian Domenico Arzu,<sup>1</sup> Riccardo Conventi,<sup>2</sup> Giovanni Putoto,<sup>3</sup> Emmanuel Onapa<sup>4</sup>

<sup>1</sup>General Surgery, Doctors with Africa CUAMM, Padua, Italy; <sup>2</sup>General Surgery, University of Modena e Reggio Emilia, Modena, Italy; <sup>3</sup>Tropical Medicine, Projects Department, Doctors with Africa CUAMM, Padua, Italy; <sup>4</sup>Aber Hospital, Aber, Uganda

## Abstract

Laparostomy is a surgical technique enabling the surgeon to leave abdominal fascial edges opened after a laparotomy. This is a useful tool that can be very important in patients with intra-abdominal hypertension. Open abdomen indications are: trauma, severe abdominal sepsis, intestinal infarction, vascular surgery and when the surgeon cannot close the abdomen due to high intra-abdominal pressure in order to avoid abdominal compartment syndrome or in case of a second look in order to evaluate the conditions of the abdomen (and particularly of the gut). We used this technique in a low income country for a patient with intestinal obstruction where performing a primary anastomosis during the first operation was at high risk of leakage.

A middle-aged woman was admitted in Pope John's Hospital - Aber, Uganda for abdominal pain and intestinal obstruction (IO) symptoms. A laparotomy found a tract of small gut necrotic and twisted under a single adhesion. The small gut above the volvulus was dilated for the obstruction created by the adhesion. We decided to excise the necrotic intestine and leave the abdomen open for a second look and delayed anastomosis and closure. The managing of the IO was conducted by inserting a big Foley catheter in the proximal intestine to drain its enteric content in a similar fashion to a *guided external fistula*.

Open abdomen is a very important technique, relatively new, that can impact positively in treating some surgical patients even

in rural hospitals and in the absence of Intensive Care Unit. A simple trick can solve successfully the IO due to the volvulus. Laparostomy should be spread more in African and low-income countries.

## Case Report

A 42(?) -year old woman came to Aber Hospital at around 7:00 p.m. and was admitted in October 2015 to the surgical ward complaining severe abdominal pain, she was not passing stools and flatus for the past 5 days and she had no history of previous surgeries. The patient was hemodynamically stable, although slightly tachycardic (BP 100/70, HR 100 bpm). Clinically she presented with severe abdominal distension and signs of peritonitis. Rectal exploration was carried out at hospital admission showing empty rectus. We tried to manage this case conservatively by passing a rectal tube thinking it could have been a sigmoid volvulus, very frequent in African communities but after a plain abdominal XR we realized the distension was coming from the small gut. Blood tests showed a mild leukocytosis, normal Hb and PLT. The patient started resuscitation fluids, IV antibiotics, and pain relief, we passed a NGT and urinary catheter. An explorative laparotomy was planned the following day: despite she was slightly peritonitic at presentation, it was impossible to set up the theatre and perform the operation sooner due to logistic deficiency. The NGT output before the operation was about 100 mls and urine output about 1500 mls. The operation was undertaken the following morning, as soon as it was possible to arrange the theatre (around 8:00 a.m.), and the patient's vital signs were stationary from the former evening. The patient was premedicated with diazepam and pethidine. General anesthesia was induced with an iv ketamine bolus and iv suxamethonium, then maintained with ketamine iv in continuous drip (due to lack of inhalation anesthetic drugs) and atracurium. Both induction and maintenance were carried on by a Technician in Anesthesia, due to the lack of Doctors specialized in Anaesthesia. We performed a laparotomy (midline over and below the umbilicus) finding a small gut intestinal infarction due to a kinking under an adhesion. A fast but accurate exploration of the abdomen showed presence of matt fluid. Proximal bowel loops appeared distended up to Treitz ligament (about 4 cm in diameter), thickened, hyperemic, edematous and paralytic. Distal ones appeared empty. The necrotic loop was located at about 3 m from Treitz and at about 30 cm from the ileo-cecal junction, with a total extension of about 1.5 m. We performed an intestinal resection of the necrotic gut about 1.5 m wide (Figure 1, proximal extremity of the ileal loop on the lower side of the picture), closing both of the

Correspondence: Gian Domenico Arzu, General Surgery, Doctors with Africa CUAMM, via San Francesco 126, 35121 Padua, Italy.  
E-mail: argia01@gmail.com

Key words: Open abdomen; laparostomy; intestinal obstruction; African countries.

Received for publication: 18 August 2016.  
Revision received: 10 December 2016.  
Accepted for publication: 18 January 2017.

©Copyright G.D. Arzu et al., 2017  
Licensee PAGEPress, Italy  
Journal of Peritoneum (and other serosal surfaces) 2017; 2:31  
doi:10.4081/joper.2017.31

This article is distributed under the terms of the Creative Commons Attribution Noncommercial License (by-nc 4.0) which permits any non-commercial use, distribution, and reproduction in any medium, provided the original author(s) and source are credited.

extremities of the resection with continuous Vicryl 3/0 seromuscular sutures. We decided not to anastomize primarily the vial remaining segments because resection edges appeared suffering and of different size. Therefore, since during the operation we noticed that local conditions of the surgical field did not allow a safe anastomosis, we decided to leave the abdomen opened. To avoid peritoneal contamination (there was even no availability of reliable sucking devices) and to spare time we decided not to drain the intestinal fluids of the distended gut by opening the small intestine. Thus, we inserted in the distal tract of the upper resection, through an enterotomy on the antimesenteric side of the ileum, a big Foley catheter (n. 22) fixed with a double purse string with the purpose of derivating the intestinal content of the distended intestine outside (Figure 2). The abdominal wall was left opened likewise a laparostomy, protecting the abdominal content with a sterile plastic urine bag sutured with Vicryl 3/0 to the fascial edges (Bogota bag) (Figure 3).<sup>1</sup> The duration of the whole operation was approximately one hour. It is possible that in another setting (a hos-

pital supplied with more resources), the author might have opted for another operation and would have probably performed a primary anastomosis draining the intestinal obstruction during the same procedure, but in a rural hospital everything should be done to minimize the post op complications. The woman was sent in surgical ward for resuscitation and stabilisation, as the ICU is unavailable. In the I POD the discharge of intestinal content was about 400 mls and the following day, before taking again the patient to the theatre, about 700 mls. After 48 hours the patient was brought back to the theatre for the second look operation. We found a very detended intestine and no signs of peritonitis. After removal of the Foley catheter we proceeded to perform an ileo-ileal side-to-end anastomosis with an interrupted Vicryl 3/0 single layer suture. The gut appeared vial, vital and patent. Finally we closed the muscular sheath using a Nylon n. 2-interrupted suture without need of detensive incisions on the pararectal fascial edges (Figure 4). Skin was sutured using Nylon 2 interrupted stitches. The PO period was uneventful and without any complication, the patient was dis-

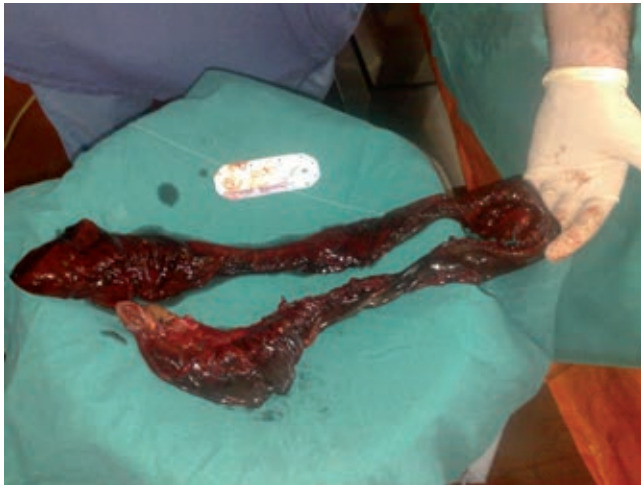

Figure 1. Resected necrotic gut.

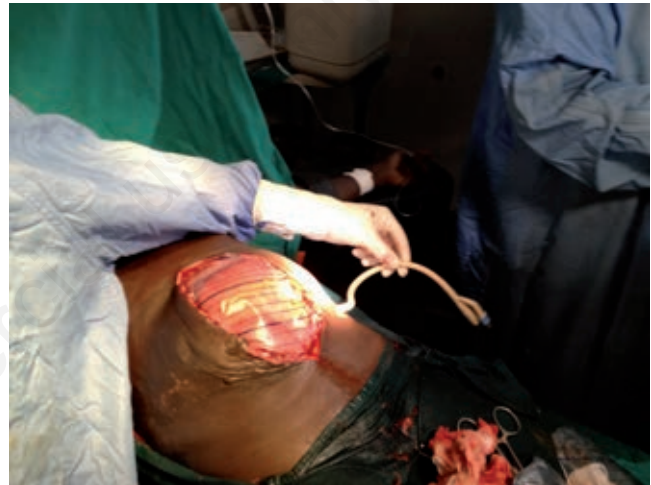


Figure 3. Bogota bag in place.

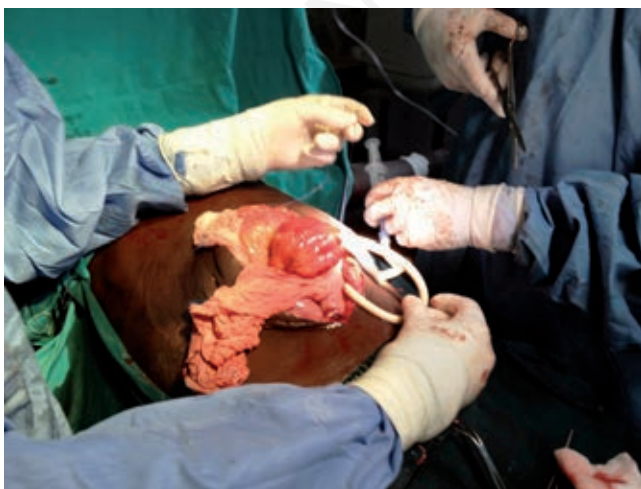

Figure 2. Derivating the intestinal content using a big Foley catheter.

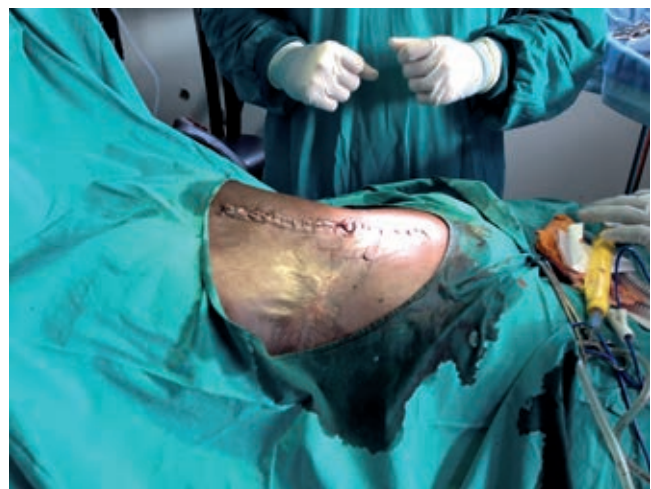

Figure 4. Abdominal wall closed after the second-look operation.

charged in 8 POD after the second operation. No major clinical problems were found at the follow up. No previous literature is present regarding this technique in rural Uganda.

---

## Discussion

The aim of this paper is to show that it is possible to carry out the open abdomen technique with limited resources. It is well known and accepted that laparostomy is useful in many cases in which closing the abdominal wall can be dangerous and at risk of developing high intra abdominal pressure.<sup>2,3</sup> Open abdomen allows surgeons to abbreviate initial surgery in very severe compromised patients and relook surgery in patients with ongoing sepsis. It can prevent abdominal compartment syndrome<sup>4</sup> until the patient is appropriately resuscitated and hemodynamically stable but also it permits to delay intestinal anastomosis<sup>5</sup> avoiding stoma formation and enables the surgeon to revise the abdominal cavity regularly and to check the efficacy of the drainage without repeated damages to the abdominal wall.<sup>6</sup>

Stage laparotomy was initially described in trauma setting, with resection of injured bowel without anastomosis and returning to complete GI reconstruction once the patient is stable and more likely to heal.<sup>7</sup>

Especially in poor countries open abdomen may prove to be a useful surgical option in those patients having severe sepsis and septic shock, but also in more stable patients and less severe diseases as a substitute of the so called *on demand* strategy.<sup>2,8-12</sup> This patient had three reasons to develop acute abdomen (vascular, mechanical and septic), resulting in a surgical indication as the patient developed intestinal necrosis and small bowel obstruction due to the single adhesion and secondary peritonitis due to the bacterial translocation and potentially contamination of the surgical field with enteric fluid.

In patients with compromised tissue perfusion, primary anastomosis is at high risk of anastomotic leakage resulting in increased mortality. In these patients, consideration should be given to initially control the source of peritoneal contamination and delay the bowel anastomosis.<sup>13,14</sup> The open abdomen procedure is a significant surgical advance, as part of damage control techniques in severe abdominal trauma.<sup>15</sup> Surgeons should be aware of the pathophysiology of severe intra-abdominal sepsis and always keep in mind the option of open abdomen in order to be able to use it in the right patient at the right time. However, the use of this technique has been described in very modern contests, but only few Authors relate about their experience in poor countries where human and technical resources are limited.<sup>16</sup> In low income countries, surgery is not widely recognized as a public health issue.<sup>17</sup> The first and usual application of laparostomy is for management of traumas and abdominal sepsis. Nevertheless, many further indications were afterwards found as appropriate applications of open abdomen.<sup>13</sup> Thus it is advisable every time the closure of the abdominal wall is not possible or determines a high risk of complication with need of relaparotomy.<sup>18</sup> With this kind of operation, revisions allow to identify quickly anastomotic dehiscences or any problem that can occur into the abdomen.<sup>19</sup> Caronna *et al.* hypothesised the usefulness of laparostomy for the early diagnosis and treatment of complications in management of typhoid intestinal perforation in rural hospital in northwestern Benin.<sup>19</sup> Open abdomen procedure is defined as intentionally leaving the fascial edges of the abdomen un-approximated (laparostomy). The abdominal contents are exposed and protected with a temporary coverage.<sup>20,21</sup> The choice of submitting this

case to an open abdomen technique was due to the previous experience of the senior surgeon in the same hospital. An abrupt power cut can bring huge complications even to routine surgery. We performed a very similar operation of IO in a younger woman and during the procedure, at the time of suction of the intestinal content, suddenly the power was off: despite our efforts, the result was the massive contamination of the abdomen with a very poor control source.<sup>22,23</sup> What is it possible with so limited resources? Can we perform lightly a primary ileostomy and condemn the patient to a hard time until the closure of the ileostomy is possible (if it will ever be) or can be done? Are we sure about the presence of a surgeon able to close the stoma after the complete recovery of the patient? Making an anastomosis and waiting the almost sure breakdown of the anastomosis in a contaminated field? How to manage the much distended bowel, minimizing the surgical procedure and the possible complications? Why don't we try an open abdomen procedure with a simple trick performable everywhere? The problems we faced with were the intestinal obstruction, the peritonitis secondary to the intestinal necrosis, the necrotic intestine to be resected, the anastomosis to be performed. The case we present is about IO due to a volvulus with intestinal necrosis of the small gut treated with damage control techniques. We feel that open abdomen technique is helpful in treating intestinal obstruction, especially in the absence of intensive care unit. The placement of a big Foley catheter creating an external enteric fistula can be useful to solve *naturally* the distension and intestinal edema, avoiding the contamination of the abdomen. Improvements in understanding and preventing paralytic ileus through changes in postoperative care and, we suppose more importantly, in the managing of the operation, may facilitate recovery of gastrointestinal function after abdominal surgery, avoiding the so feared acute gastrointestinal failure in the postoperative patient.<sup>8</sup> An important challenge is also to explain to the all staff (particularly to the anesthetists) this very new technique that may seem so far to the very aggressive routine approach.<sup>24</sup> With limited resources available open abdomen technique remains a big challenge in poor countries. In order to succeed in this great challenge it is important to understand the pathophysiology of abdominal hypertension<sup>25</sup> and spread the new knowledge among physicians and surgeons working in low-income hospitals.<sup>26</sup> Even in case of scarce resources, the concept of damage control surgery and its application with tension-free closure of the abdominal wall after abbreviated laparotomies can increase survival rates in critical patients.<sup>27</sup> Moreover the awareness of the potential complications for clinicians and staff using laparostomy should be mandatory not to turn a good surgical tool into malpractice.<sup>28</sup>

---

## Conclusions

Laparostomy is a safe and feasible procedure in low-income countries and it should be supported.

We found this simple trick (insertion of a big Foley), more physiological in draining the intestinal content than squeezing the intestinal content up through the NG tube or sucking the bowel through a new opening of the gut with the risk of contamination and poor source control. This simple procedure obtained almost complete normalization of the abdominal surgical field, restoring the normal size of the intestine without traumatic procedures. In low-income countries it is advisable to manage complicated intestinal obstruction with laparostomy, in opposite to rich countries where technical resources are not comparable.

## References

1. Sherck J, Seiver A, Shatney C, et al. Covering the "open abdomen": a better tech-nique. *Am Surg* 1998;64:854-7.
2. Stagnitti F. Intestinal occlusion and abdominal compartment syndrome (ACS). *Ann Ital Chir* 2009;80:417-21.
3. Atema JJ, Gans SL, Boormeester MA. Systematic review and meta-analysis of the open abdomen and temporary abdominal closure techniques in non-trauma patients. *World J Surg* 2015; 39:912-25.
4. Bjorck M, Wanhainen A. Management of abdominal compartment syndrome and the open abdomen. *Eur J Endovasc Surg* 2014;47:279-87.
5. Ordoñez CA, Pino LF, Badiel M, et al. Safety of performing a delayed anastomosis during damage control laparotomy in patients with destructive colon injuries. *J Trauma* 2011;71: 1512-7.
6. Richon J, Le Coultre C, Meyer P, et al. Laparostomy in children. *Z Kinderchir* 1985;40:224-7.
7. Morris Jr JA, Eddy VA, Blinman TA, et al. The staged celiotomy for trauma. Issues in unpacking and reconstruction. *Ann Surg* 1993;217:576-84.
8. Carlson GL, Dark P. Acute intestinal failure. *Curr Opin Crit Care* 2010;16:347-52.
9. Van Ruler O, Mahler CW, Boer KR, et al. Comparison of on-demand vs planned re-laparotomy strategy in patients with severe peritonitis: a randomized trial. *JAMA* 2007;298:865-72.
10. Scriba MF, Laing GL, Bruce JL, Clarke DL. Repeat laparotomy in a developing world tertiary level surgical service. *Am J Surg* 2015;210:755-8.
11. Soressa U, Mamo A, Hiko D, Fentahun N. Prevalence, causes and management out-come of intestinal obstruction in Adama Hospital, Ethiopia. *BMC Surg* 2016;16:38.
12. Scriba MF, Laing GL, Bruce JL, et al. The role of planned and on-demand relaparotomy in the developing world. *World J Surg* 2016;40:1558-64.
13. Carlson GL. Surgical management of intestinal failure. *Proc Nutr Soc* 2003;62:711-8.
14. Sartelli M, Abu-Zidan FM, Ansaloni L, et al. The role of the open abdomen procedure in managing severe abdominal sepsis: WSES position paper. *World J Emerg Surg* 2015;10:35.
15. Regner JL, Kobayashi L, Coimbra R. Surgical strategies for management of the open abdomen. *World J Surg* 2012;36: 497-510.
16. De Siqueira J, Tawfiq O, Garner J. Managing the open abdomen in a district general hospital. *Ann R Coll Surg Engl* 2014;96:194-8.
17. Citron I, Chokotho L, Lavy C. Prioritisation of surgery in the national health strategic plans of Africa: a systematic review. *World J Surg* 2016;40:779-83.
18. Papavramidis TS, Marinis AD, Pliakos I, et al. Abdominal compartment syndrome - Intra-abdominal hypertension: defining, diagnosing, and managing. *J Emerg Trauma Shock* 2011; 4:279-91.
19. Caronna R, Boukari AK, Zaongo D, et al. Comparative analysis of primary repair vs resection and anastomosis, with laparostomy, in management of typhoid intestinal perforation: results of a rural hospital in northwestern Benin. *BMC Gastroenterol* 2013;13:102.
20. Leppäniemi AK. Laparostomy: why and when? *Crit Care* 2010;14:216.
21. Campbell AM, Kuhn WP, Barker P. Vacuum-assisted closure of the open abdomen in a resource-limited setting. *S Afr J Surg* 2010;48:114-5.
22. Marshall JC, al Naqbi A. Principles of source control in the management of sepsis. *Crit Care Clin* 2009;25:753-68.
23. De Waele JJ. Early source control in sepsis. *Langenbecks Arch Surg* 2010;395:489-94.
24. Demetriades D. Total management of the open abdomen. *Int Wound J* 2012;9:17-24.
25. Cheatham ML, Safcsak K. Intra-abdominal hypertension and abdominal compartment syndrome: the journey forward. *Am Surg* 2011;77:S1-5.
26. Kuteesa J, Kituuka O, Namuguzi D, et al. Intra-abdominal hypertension; prevalence, incidence and outcomes in a low resource setting; a prospective observational study. *World J Emerg Surg* 2015;10:57.
27. Balandraud P, Biance N, Peycru T, et al. Abbreviated Laparotomy for treatment of severe abdominal trauma: use in austere settings. *Med Trop (Mars)* 2007;67:529-35.
28. Decadt B, Siriwardena A. Small-bowel obstruction secondary to subcutaneous small-bowel entrapment: a late complication of laparostomy for necrotizing pancreatitis. *Int J Pancreatol* 2001;29:117-20.